

# CARPAL TUNNEL EXPANSION BY STRETCHING THE TRANSVERSE CARPAL LIGAMENT

Zong-Ming Li, Jie Tang, Matthew C. Chakan, Rodrigo Kaz, Ashish D. Nimbarte

Hand Research Laboratory, Departments of Orthopaedic Surgery and Bioengineering, University of Pittsburgh

## INTRODUCTION

The transverse carpal ligament (TCL) forms the palmar roof of the carpal tunnel and plays a critical role in regulating carpal tunnel mechanics [1,2]. The mechanical constraint of the TCL predisposes the median nerve to compression and the ensuing carpal tunnel syndrome. Transecting the TCL, whether by open or endoscopic carpal tunnel release procedures, is the standard surgical treatment of carpal tunnel syndrome. Even though carpal tunnel release has existed for over 70 years, we have limited knowledge of the mechanical properties of the carpal tunnel and the TCL. Common complications and recurrence associated with TCL transection continues to challenge us to develop alternative CTS treatments without cutting the TCL [3,4]. Yet, understanding carpal tunnel mechanics is critical to the development of such alternatives. The purpose of this study was to investigate the expansion of the carpal tunnel with palmarly directed force on the TCL from inside the carpal tunnel.

## METHODS

Five fresh frozen cadaveric hands were dissected to expose the TCL by removing the skin, fascia, and fat while the ligament insertion sites to carpal bones were intact. The TCL was recognized by its transverse fibers and insertions at the pisiform, hook of hamate, tuberosity of scaphoid and ridge of trapezium (Figure 1). The flexor tendons and median nerve were also removed to clear the carpal tunnel. The bony surface within the carpal tunnel was digitized to determine the cross-sectional area formed by carpal bones. Then specimen was mounted on a dorsal support in full supination and approximately 20° of wrist extension on a custom platform. A lever, which rotated about a suspended, threaded rod, was inserted under the central line of the TCL so that the midpoint of the central line located 150 mm from the lever's fulcrum. The lever was then made parallel to the table surface and loaded, at a distance of 450 mm from the fulcrum. With this lever device, the TCL was stretched by a palmarly directed force from within the carpal tunnel. A steel plate passed through the carpal tunnel to stabilize the hand. The palmar surface of the TCL was digitized while the TCL is being stretched using a 3D digitizer. Eight constant force levels were applied to the TCL, ranging from 10 N to 200 N. The cross-sectional area was determined at the middle level between the trapezium and scaphoid.

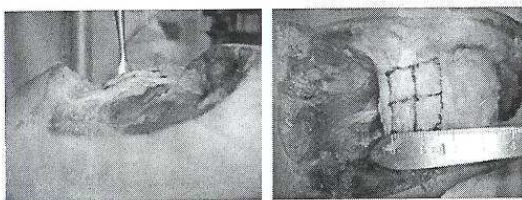


Figure 1. Cadaveric preparation of the carpal tunnel (left) and the transverse carpal ligament (right)

## RESULTS

The area defined by the carpal bones without the TCL-formed arch was  $128.2 \pm 24.2 \text{ mm}^2$ . The TCL formed an arch that expanded the carpal tunnel with increasing loading (Figure 2). With the TCL stretching and arch formation, the cross-sectional areas of the carpal tunnel were  $165.0 \pm 24.9 \text{ mm}^2$  at 10 N, and  $194.3 \pm 21.4 \text{ mm}^2$  at 200 N, representing increases of 28.7% and 51.6%, respectively. The TCL arch heights were  $2.8 \pm 0.3 \text{ mm}$  at 10 N and  $5.4 \pm 0.4 \text{ mm}$  at 200 N.

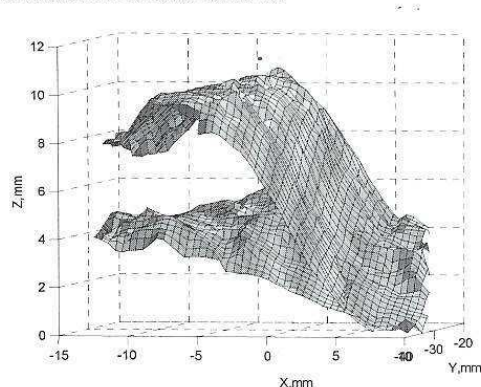


Figure 2. Surface plot of the transverse carpal ligament before and after stretching

## DISCUSSION

Our study demonstrates the stretchability of the TCL and the resulting expansion of the carpal tunnel. The result of about 30% carpal tunnel expansion by a small stretching force of 10 N suggests that the TCL is accommodating with the variation of carpal tunnel pressure in a physiological environment. Greater than 50% carpal tunnel expansion is available under relatively large stretching force (> 200 N). Future studies are needed to investigate the viscoelastic properties of the TCL and to explore the potential of permanent residual deformation. The mechanical properties of the TCL may be exploited for the development of alternative carpal tunnel syndrome treatments, such as manipulative procedures [3] and balloon carpal tunnel plasty [4].

## ACKNOWLEDGEMENTS

The Pittsburgh Foundation, Ferguson Orthopaedic Fund.

## REFERENCES

- [1] Brooks et al., Clin Biomech 2003, 18(8): p. 685-93
- [2] Kirititsis & Kline, J Hand Surg 1995, 20(2): p173-80
- [3] Sucher, J Am Osteopath Assoc 1993. 93(12): p. 1273-8
- [4] Berger, Personal communications. 2005